M. Faerman, U. Zilberman, P. Smith
Department of Anatomy and Embryology, Hadassah Medical School, Hebrew University, Jerusalem, Israel

V. Kharitonov, V. Batsevitz
Museum and Research Institute of Anthropology, Moscow State University, Moscow, Russia

Received 16 July 1993
Revision received 10 February 1994 and accepted 13 February 1994

Keywords: Barakai, Neanderthal, mandible, teeth.

A Neanderthal infant from the Barakai Cave, Western Caucasus

The mandible of the infant found in Mousterian context in the Barakai Cave, Western Caucasus, displays a suite of distinctively Neanderthal characteristics, expressed in the size and shape of the mandible and teeth, absence of chin and taurodontic teeth with extremely thin enamel. The stage of dental development suggests an age of 3 years relative to standards for modern children. When compared to Neanderthal mandibles of children of similar dental age the Barakai mandible is relatively large and robust.

Journal of Human Evolution (1994) **27**, 405–415

Introduction

In 1979 the mandible of a Neanderthal child was found in the Barakai Cave, Western Caucasus (Figure 1). This is the third Neanderthal child's mandible to be discovered in

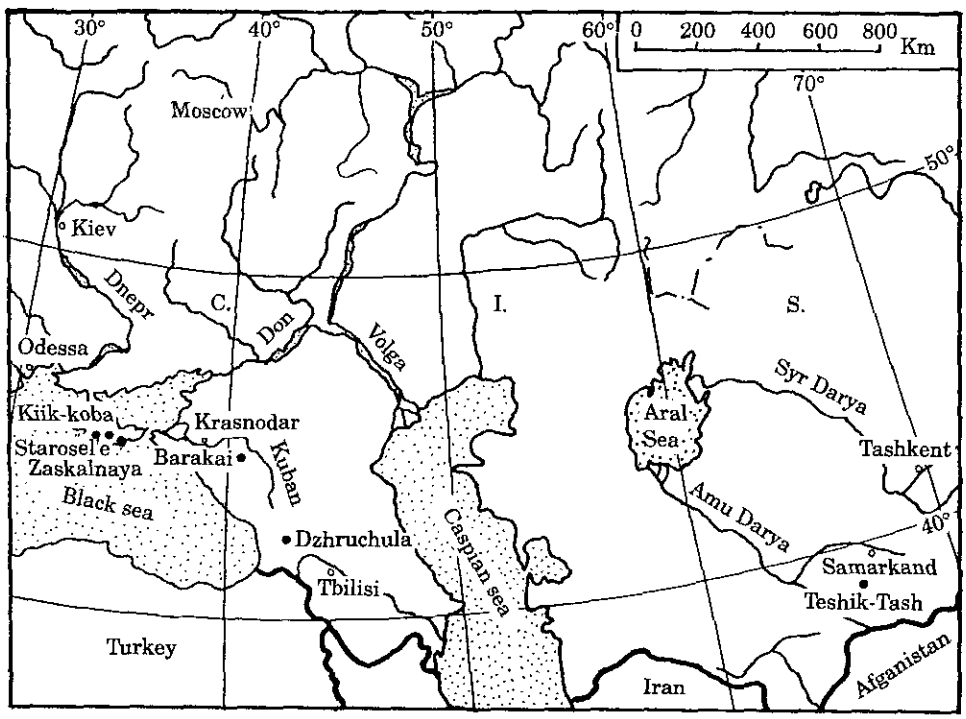

Figure 1. Map showing the location of Barakai relative to other Middle Palaeolithic sites in the Commonwealth of Independent States (former USSR).

0047-2484/94/050405+11 $08.00/0

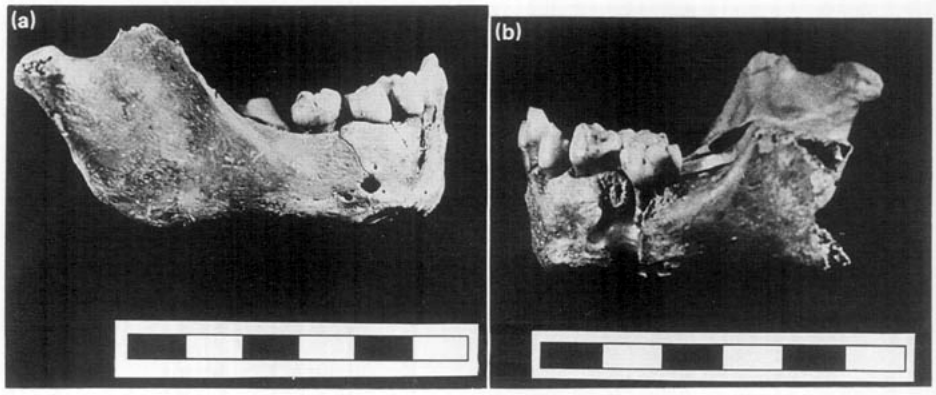

Figure 2. Lateral view of the Barakai mandible. (a) right side; (b) left side. Note the rounded shape of the mental foramen and accessory foramena.

Figure 3. Occlusal view of the Barakai mandible.

the former Soviet Union, and with a dental age of 3 years is one of the youngest yet found. The mandible which was almost complete was described by Lyubin *et al.* (1986) in an article published in Russian. The present article provides a short description of the site and the specimen as well as new data on dental development and the internal structure of the teeth.

The Barakai site, is located in the middle part of the Kuban River Basin, on the northern slope of Skalistij Ridge, Borysovskij Canyon, approximately 160 kilometers south-east of Krasnodar City. The site is approximately 900 meters above sea level, and is one of numerous

Table 1 Comparison of the metric values of the Barakai mandible with those of Near Eastern and European Neanderthals

Site Measurement (mm)	Barakai	Pech de l'Aze	Molare 1	Roc de Marsal	La Chaise 13	Archi	Devil's Tower 2
Height of the symphysis	24·1	19	25·7	20·4	22·1	22	21·2
Height of the body at dm1-dm2	20·1	15·5	20·9	17·0	20·5	20·8	22·8
Height of the body at foramen mentale	19·2	—	—	—	—	—	—
Thickness at symphysis	12·5	—	(14·0)	12·5	12·8	—	12·6
Thickness of the body at dm1-dm2	14·2	11·5	12·2	13·1	12·5	11·9	13·6
Thickness of the body at foramen mentale	13·5	—	—	—	—	—	—
Bimental width	40·0	—	—	—	—	40·6	—
Length of the anterior alveolar arch	26·0	—	—	28·4	27·8	27·8	(25·6)
Breadth of the anterior alveolar arch	50·0	—	60·0?	50·8	(52)	44	(53·4)
Height of the ramus	36·2?	27·5	—	32·4	—	—	43·3
Minimum breadth of the ramus	26·1	23·5	—	26·4	—	—	26·8
Body length	55·9	62	—	—	—	—	—
Maximum mandibular length	78·1	67	—	71·0	—	—	—
Index of robustness at dm1-dm2	70·6	74·2	58·3	77·0	60·9	57·2	59·6
Index of robustness at foramen mentale	70·3	—	—	—	—	—	—
Index of robustness at the symphysis	51·9	—	(54·5)	61·3	57·9		59·4
Index of the anterior alveolar arch	52	—	—	55·9	54·7	63·2	47·9
Angle of the chin	84°	92°30	79°	75°	85°	81°	79°
Angle of the ramus	124°	133°	—	—	—	—	—
Dental age, years	3·0	2–2·5	3·0	3·5	3·5	3·0	4·0

Note: Data on Pech de l'Aze are taken from Ferembach (1970); Rock de Marsal, La Chaise 13 and Devil's Tower 2—from Tillier (1983); Molare—from Mallegni & Ronchitelli (1987); Archi—from Ascenzi & Segre (1971).

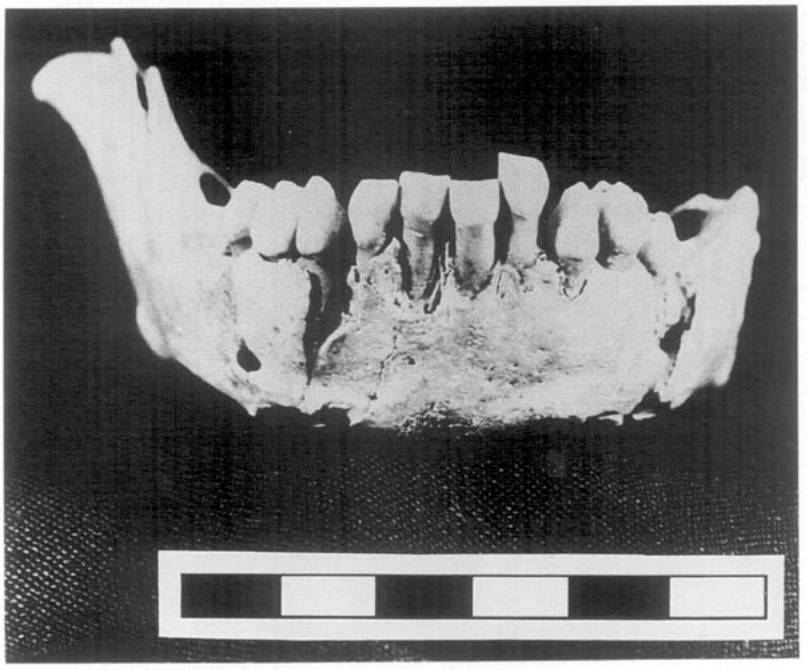

Figure 4. Frontal view of the Barakai mandible.

limestone caves, rock-shelters and niches situated there. The cave was found in 1976 and excavated in 1977–1980 by the Palaeolithic Expedition of the Institute of Archaeology, Leningrad Division of the Academy of Sciences (Prof. Lyubin) and Adygeiskij Research Institute (Prof. Autlev).

A rockfall had blocked part of the cave, leaving approximately 35 m^2 accessible. Two distinct layers were identified in the Barakai site: a Late Holocene level, which is 0·60 m thick, and an Upper Pleistocene level, which is up to 0·25 m thick in places, and has been assigned to the end of Wurm II.

The Upper Pleistocene layer was very rich in cultural remains. An area of 15 m^2 was excavated, which was 10–25 cm thick, and yielded nearly 80 thousand bone fragments and more than 21 thousand flints (only findings exceeding 0·2–0·3 cm in size were taken into account). Faunal remains included bones of bisons, Caucasian goats, Asian moufflons, horses, pikas, susliks and hamsters, and a child's mandible.

The flint-working technique of the Barakai cave is rather primitive, although inhabitants of the cave were familiar with Levallois and prismatic techniques. The flint industry is represented by a large number of tools of the Mousterian type with relatively high incidence of scrapers (46·6%) and "notched" tools (41·0%). Points of the Mousterian (arrow-shaped, leaf-shaped and asymmetrical) and Levallois types were also found, generally not exceeding 4 cm in length and less than 0·72 cm thick. The flint industry of the Barakai cave was identified as typical Mousterian, similar to that found at Kiik-Koba and La Micoque.

The child's mandible was found on its base with the symphysis pointing to the south-east, in the lower part of the Upper Pleistocene level, some 3–4 cm above the floor of the

Table 2 Mediodistal (MD) and buccolingual (BL) measurements of lower deciduous teeth of the Barakai child compared with the mean values recorded for Near Eastern and European Neanderthals and Near Eastern early *Homo sapiens sapiens*

Variable (mm)		*H.s.s.*		*H.s.n.*		Barakai	
		MD	BL	MD	BL	MD	BL
dm2	N	5	5	17	17		
	X	10·47	9·30	10·40	9·40	11·00	10·10
	S.D.	0·61	0·40	0·70	0·50		
	Min	10·00	9·00	8·40	8·40		
	Max	11·30	10·00	11·30	10·20		
dm1	N	4	4	15	15		
	X	8·77	7·51	8·90	7·40	9·10	7·60
	S.D.	0·21	0·16	0·40	0·50		
	Min	8·50	7·30	8·00	6·20		
	Max	8·95	7·70	9·90	8·60		
dc	N	4	3	9	8		
	X	6·66	6·00	6·85	6·13	7·05	6·20
	S.D.	0·48	0·36	0·59	0·54		
	Min	6·00	5·60	5·70	5·30		
	Max	7·15	6·30	7·80	7·05		
di2	N	4	4	4	4		
	X	5·38	4·99	5·40	5·02	6·15	5·15
	S.D.	0·29	0·15	0·45	0·42		
	Min	5·07	4·85	5·03	4·60		
	Max	5·70	5·20	6·00	5·60		
di1	N	3	3	6	6		
	X	4·84	4·70	5·01	4·59	5·70	4·55
	S.D.	0·21	0·10	0·31	0·37		
	Min	4·60	4·60	4·60	4·00		
	Max	5·02	4·80	5·40	5·10		

Note: Data on early *Homo sapiens sapiens* (*H.s.s.*) are given after P. Smith and A.-M. Tillier (1989, pp. 330–331). Average means for *Homo sapiens neanderthalensis* (*H.s.n.*) are based on data published by F. Mallegni & A. T. Ronchitelli (1989), P. Smith & B. Arensburg (1977) and A.-M. Tillier (1979).

cave. It was nearly complete, lacking only the left ramus which may have been broken by rockfall.

Morphology of the Barakai mandible

The Barakai mandible is large and rounded and demonstrates several archaic traits. In the lateral view, the symphyseal contour forms an obtuse angle with the base of the mandible (Figure 2). There is no true chin, and the alveolar border projects anteriorly. There is, however, a slight low triangular elevation, *trigonum mentale*, in the median line. The *tubercula lateralia* are faintly delimited. But there is no *incurvatio mandibulae anterior*. The *trigonum mentale* is more pronounced than in the juvenile Teshik-Tash and Zaskalnaya VI specimens described by Kolossov *et al.* (1985).

The anterior part of the Barakai mandible is rounded with no distinct angle separating the anterior and lateral portions. In the frontal view, there is no "rib-break", as defined by Gremyatskij (1949) to describe the separation between the frontal part and the lateral portion of the mandible in the Teshik-Tash specimen. The basal view also confirms the absence of frontal flattening, and the buccally placed deciduous molars.

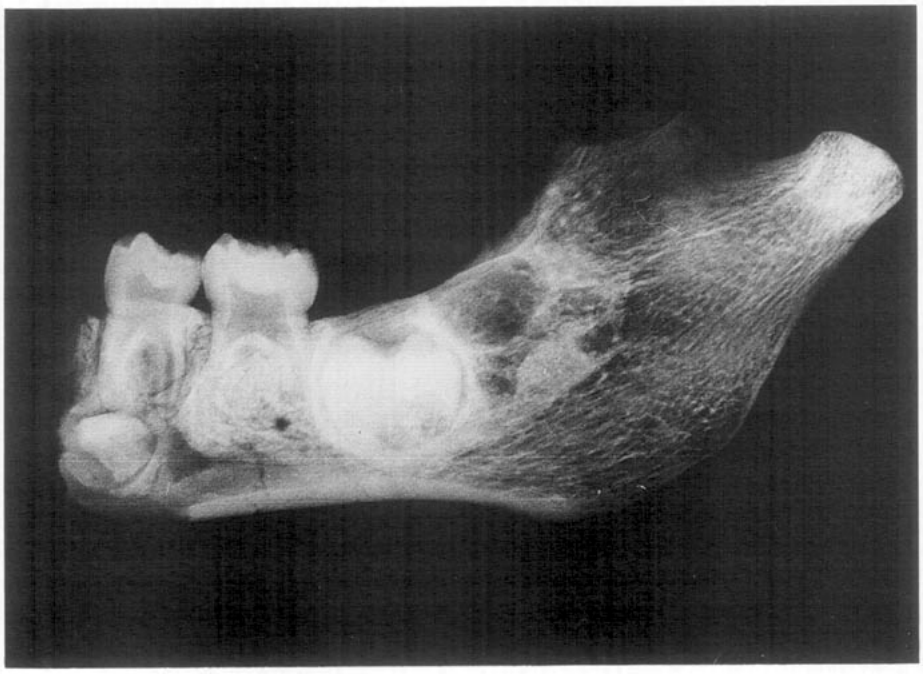

Figure 5. Radiographs of the right side of the mandible showing incomplete roots of the second deciduous molar and completed crown formation on the first molar. Note taurodontism of deciduous molars and thin enamel.

The basal and alveolar parts of the Barakai mandible are equally developed. There is a large mental foramen and three small accessory foramina on the right side of the Barakai mandible. The left side is damaged but mental foramina on both sides of the mandible appear to be the same size and are located opposite to the first deciduous molars. The ascending ramus is very broad and obtuse angled with the coronoid process higher than the condylar process. The head of the condylar process in Barakai is elongated, and its superior surface is nearly flat. The neck of the condylar process is short as in Teshik-Tash. The mandibular notch is shallow and broad. The area of insertion of the masseter and pterygoid muscles are well defined. A distinct torus can be seen on the internal border of the coronoid process. This is separated from the lateral margin by a distinct sulcus.

The symphysis is very thick. Its inner surface is somewhat convex and saddle-shaped, according to the terminology of Gremyatskij (1949). As in Teshik-Tash the upper concavity is larger and is oriented posteriorly and superiorly, and the lower cavity is oriented inferiorly (Figure 3). Two mentail spines are faintly outlined but no distinct projection can be seen.

The sublingual fossae are poorly demarcated, but the digastric and submandibular fossae are more pronounced than in modern children. The submandibular fossae are more pronounced in the Barakai mandible than in Teshik-Tash, but the mandibular torus is less developed, and the sublingual fossae are less pronounced. The internal oblique mylohyoid line is well defined on the lingual surface and terminates posteriorly in a distinct triangular torus anterior to the mandibular foramen. This reflects well-developed muscles of the fundus of the oral cavity, in contrast to the condition in modern children of similar age.

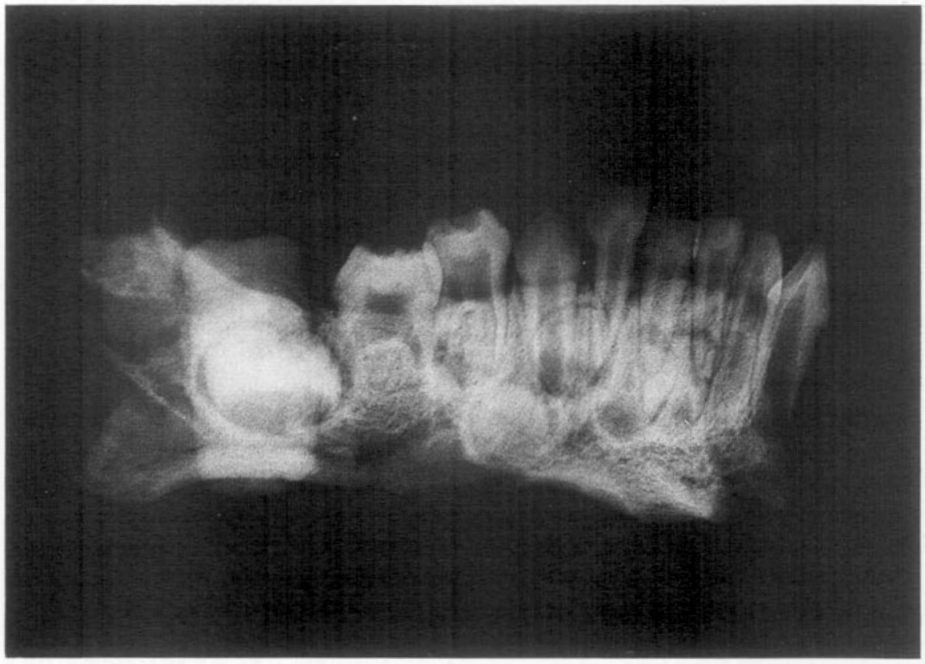

Figure 6. Radiographs of teeth of the left side and symphysis of the mandible showing incomplete roots of the deciduous canine and developing permanent teeth.

Morphometry of the Barakai mandible

Measurements of the Barakai mandible are given in Table 1 together with those of other Neanderthal specimens of approximately the same stage of dental development. In this study all specimens were aged according to radiographic standards developed by Moorrees *et al.* (1963). The Barakai mandible lies well within the range of variation of other Neanderthal mandibles of comparable dental age.

Dentition of the Barakai mandible

The Barakai mandible has a full set of deciduous teeth (Figure 4). Incisors and canines are relatively large, and the incisal edges of the incisors are slightly worn. The crowns of the lateral incisors show marked distal flanging and both incisors show slight shovelling (score 1). The distal element of the crown of the left canine forms a separate peak on the occlusal surface. Germs of the first permanent molars are deeply embedded in the alveolar bone of the mandible. There is a pronounced cingulum at the base of the first deciduous molar crown. The ridge of the trigonid is very massive and high, and there is a rudimentary paraconid. The second deciduous molars also have enlarged cingulae, but small trigonids along with highly differentiated and large talonids. There is a rudimentary paraconid on the right second deciduous molar, and a large posterior fossa. Both second deciduous molars show the typical 5Y pattern and have large protostylids. The left second deciduous molar also has a tuberculum sextum.

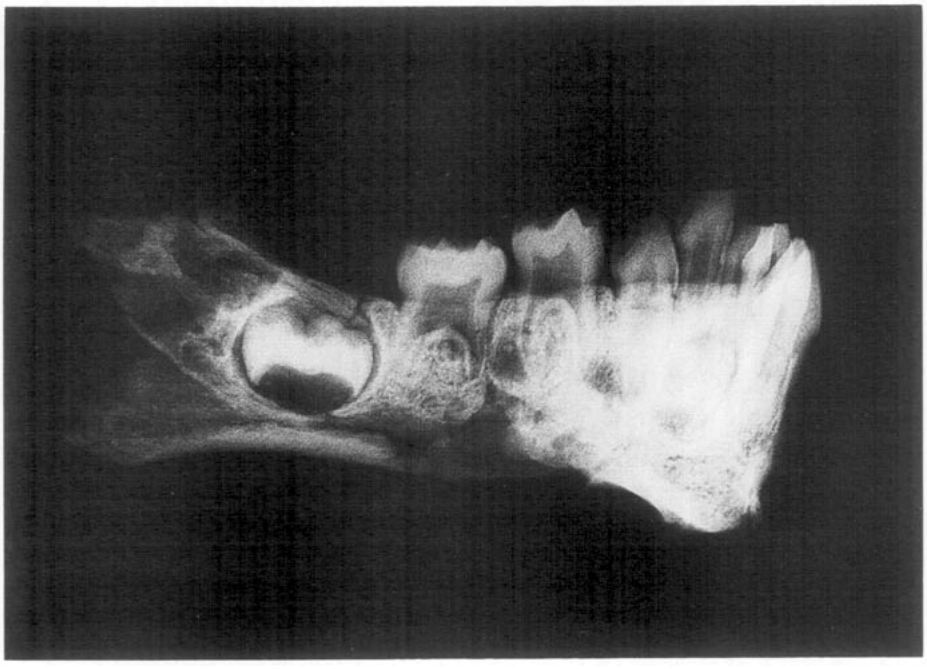

Figure 7. Radiographs of the left side of the Barakai mandible showing details of the taurodont deciduous molars and crown of unerupted first permanent molar.

Tooth size is shown in Table 2. As can be seen, the Barakai teeth are among the largest recorded for Neanderthals.

A radiograph of the right side of the mandible (Figure 5) shows that the first deciduous molar root is complete. The roots of the second deciduous molars are still incomplete and have open apices but the floor of the pulp chamber and bifurcation of the roots can be clearly seen. The partially completed crowns of the first premolar and the first permanent molar are visible within the bone. The crypts of the second premolar and the second permanent molar can also be seen though calcification of these teeth has not yet begun. The crown of the first premolar shows initial cusp formation, and the crown of the first permanent molar is three quarters complete. The central and lateral deciduous incisors roots are complete, but the root of the deciduous canine is incomplete, and the apex is wide open (Figure 6). Crowns of the permanent canine and incisors are present. The left side of the mandible shows a similar stage of tooth development (Figure 7), and the crowns of the permanent incisors can be seen in their crypts. The apex of the root of the deciduous canine is wide open. The first permanent molar crown is nearly complete. Both deciduous molars have elongated taurodont pulps.

The stages of dental development of individual teeth in the Barakai specimen and other Upper Pleistocene specimens are shown in Table 3. They demonstrate advanced development of anterior teeth relative to posterior teeth, when compared to standards derived from modern children.

Analysis of tooth components of lower deciduous molars

Tooth components of the Barakai deciduous molars were measured from radiographs using the method described by Zilberman *et al.* (1992). They found that Neanderthal deciduous teeth

Table 3 Developmental stages of lower permanent and deciduous teeth of the Barakai mandible compared to those of other Neanderthal children

	Menton 2	Pech de L'Aze	Archi	La Chaise	Roc-Marsal	Devil's Tower	Barakai
		Permanent teeth					
I1	Cr 3/4	Cr 3/4	Cr c	R 1/4	R i	R 1/4	Cr c
I2	Cr 3/4	Cr 3/4	Cr c	R 1/4	R i	R i	Cr c
C	Cr 1/2	Cr 1/2	Cr 3/4	Cr c	Cr 3/4	Cr c	Cr 3/4
Pm1	C co	C co	C co	Cr 3/4	C oc	Cr 3/4	C i
Pm2	O	O	C i	C oc	C i	Cr 1/2	O
M1	Cr 1/2	Cr 3/4	Cr 3/4	Cl i	Cr c	Cl i	Cr c
M2	—	O	—	C i	C i	Cr 1/2	O
		Deciduous teeth					
i1	A c	A c	—	—	A c	—	A c
i2	A 1/2	A 1/2	—	—	A c	—	A c
c	R 1/2	R c	A 1/2	—	A 1/2	—	R 3/4
m1	A 1/2	A c	A c	A c	A c	A c	A c
m2	R 1/2	R c	R c	A c	A 1/2	A c	R c
		Dental age (years)					
	2·0	2–2·5	3·0	3·5	3·5	4·0	3·0

Note: Radiographs examined from publications of Legoux (1965, 1966) and Skinner & Sperber (1982). Estimation of developmental stages is based on Moorrees *et al.* (1963) for permanent cheek teeth.
Key to stages of tooth formation: initial cusp formation, C i; cusp coalescence, C co; cusp outline complete, C oc; crown half complete, Cr 1/2; crown three quarters complete, Cr 3/4; crown complete, Cr c; initial root formation, R i; initial cleft formation, Cl i; root length one quarter, R 1/4; root length one half, R 1/2; root length three quarters, R 3/4; root length complete, R c; apex half closed, A 1/2; apex completely closed, A c. Note there is a discrepancy between the incisors and cheek teeth regarding stage of development. Incisor development in all specimens suggests a dental age at least one year greater than that indicated by development of cheek tooth, according to Moorrees *et al.* (1963).

show significant differences from those of *Homo sapiens sapiens* in relation to pulp size and enamel thickness. Table 4 shows measurements of tooth components of the Barakai teeth compared with the range of values previously established for Neanderthals and early *Homo sapiens sapiens*. For both deciduous molars, all values in the Barakai teeth show the typical Neanderthal patterning of thin enamel and large pulp chamber. Discriminant function analysis placed Barakai within the Neanderthal group with a degree of probability of 98·5%.

Discussion

The size and shape of the Barakai mandible places it well within the range of variation of other Neanderthal mandibles of comparable dental age, while the analysis of tooth components provides additional grounds for assigning this specimen to the Neanderthals. No attempt was made in this study to evaluate the precise developmental age of this individual. Accelerated dental development in Neanderthals relative to modern populations, and its significance in terms of evolutionary trends in life histories has been the subject of considerable discussion (Dean *et al.*, 1986; Mann *et al.*, 1991; Smith, 1991; Tillier, 1992; Tompkins, 1993). Legoux (1966) suggested that dental development in some Neanderthals was advanced relative to that of modern humans. His hypothesis has received some support from studies carried out by Dean *et al.* (1986). They determined that perikymata counts in the teeth of the Gibraltar child

Table 4 Individual values of tooth components in Barakai lower deciduous molars compared to those of Neanderthals and early *Homo sapiens sapiens*

	First deciduous molars				Second deciduous molars			
	H.s.s.	*H.s.n.*	Barakai	*p* value	*H.s.s.*	*H.s.n.*	Barakai	*p* value
EH No	36	12	2		54	13	2	
X	0·74	0·63	0·72	0·0605	1·10	0·83	0·99	0·0001
S.D.	0·20	0·15	—		0·34	0·16	—	
Min	0·20	0·41	0·70		0·42	0·50	0·98	
Max	1·08	0·95	0·74		1·91	1·08	0·99	
EW No	33	12	2		51	13	2	
X	0·61	0·48	0·58	0·0025	0·80	0·65	0·82	0·0002
S.D.	0·14	0·11	—		0·19	0·08	—	
Min	0·30	0·32	0·55		0·39	0·49	0·78	
Max	0·95	0·70	0·60		1·22	0·82	0·85	
DH No	34	12	2		53	13	2	
X	2·00	2·01	2·19	0·9407	2·57	2·38	2·70	0·0315
S.D.	0·30	0·26	—		0·39	0·23	—	
Min	1·16	1·65	2·18		1·69	1·97	2·68	
Max	2·53	2·32	2·20		3·39	2·75	2·72	
PH No	32	12	2		50	13	2	
X	1·21	2·59	3·71	0·0001	1·00	2·61	3·48	0·0002
S.D.	0·57	0·79	—		0·51	0·84	—	
Min	0·22	1·19	3·56		0·30	0·88	3·34	
Max	2·30	3·46	3·86		2·42	3·82	3·61	
PW No	30	12	2		51	13	2	
X	3·43	4·08	4·82	0·0001	4·27	4·64	5·30	0·0234
S.D.	0·59	0·36	—		0·50	0·48	—	
Min	1·52	3·28	4·74		3·20	3·80	5·22	
Max	4·80	4·62	4·79		5·35	5·55	5·39	
CW No	34	12	2		52	13	2	
X	7·95	8·51	8·66	0·0022	10·25	10·16	10·55	0·5839
S.D.	0·65	0·42	—		0·56	0·54	—	
Min	6·54	7·80	8·61		6·45	9·44	10·48	
Max	9·79	9·20	8·71		11·97	11·20	10·62	

Note: enamel height, EH; enamel width, EW; dentin height, DH; pulp height, PH; pulp width, PW; crown width, CW.

Data for comparison are taken from Zilberman *et al.* (1992).

indicated that this child was 3 years although crown and root development indicated an age of 4–5 years when compared against modern children. A number of more recent studies (Mann *et al.*, 1991, 1993; Tompkins, 1993) have demonstrated the wide range of variation in dental development of both modern and fossil hominids. While sample sizes may still be too small for valid conclusions regarding significantly advanced dental development in Neanderthals, the Barakai infant provides an additional example of a Neanderthal with advanced development of anterior relative to posterior teeth.

Mandibular form as well as tooth structure rank the Barakai child with the Classic Neanderthals of Europe. Indeed, it ranks among the largest Neanderthal mandibles known relative to its state of dental development and vividly recalls Krapina in degree of taurodontism. Since there are yet no exact dates for Barakai, the possibility of a chronological versus a geographical cline in Neanderthal mandibular and dental morphology cannot be examined at this stage.

References

Ascenzi, M. & Segre, A. G. (1971). A new Neandertal child mandible from an Upper Pleistocene site in Southern Italy. *Nature* **233,** 280–283.

Dean, M. C., Stringer, C. B. & Bromage, T. G. (1986). Age at death of the Neanderthal child from Devil's Tower, Gibraltar and the implications for studies of general growth and development in Neanderthals. *Am. J. phys. Anthrop.* **70,** 301–309.

Ferembach, D. (1970). Le crâne de l'enfant du Pech de l'Aze. *Archs. Inst. Paleont. Hum.* **16,** 13–51.

Garrod, D. A. E., Buxton, L. M. D., Smith, E. & Bate, D. M. A. (1928). Excavation of a Mousterian rock shelter at Devil's Tower, Gibraltar. *J. R. Anthropol. Inst.* **58,** 33–113.

Gremyatskij, M. A. (1949). The skull of the neanderthal child from the cave Teshik-Tash, southern Uzbekistan (in Russian). In (M. A. Gremyatskij & M. F. Nestrukh, Eds) *Teshik-Tash: Paleolithic Man,* pp. 137–181. Moscow.

Kolossov, Y., Kharitonov, V. & Yakimov, V. (1975). Paleoanthropic specimens from the Zaskalnaja VI in the Crimea. In (R. H. Tuttle, Ed.) *Palaeoanthropology, Morphology and Palaeoecology,* pp. 419–428.

Legoux, P. (1965). Détermination de l'âge denraire de l'enfant Neandertalien du Roc-Marsal. Extrait de la *Revue Francaise d'Odonto-Stomatologie* **10,** 3–24.

Legoux, P. (1966). *Détermination de l'âge Dentaire de Fossiles de la Lignée Humaine.* Paris: Maloine, 307p.

Lyubin, V. P., Autlev, P. U., Zubov, A. A., Romanova G. P. & Kharitonov, V. M. (1986). The discovery of the Neanderthal skeletal remains at the Barakai site (the Western Caucasus) (In Russian). *Vopr. Anthrop.* **77,** 60–70. Moscow: Moscow University Press.

Mallegni, F. & Ronchitelli, A. (1987). Découverte d'une mandibule Néandertalienne a l'abri du molare pres de Scario (Salerno-Italie): Observations stratigraphiques et palethnologiques etude anthropologique. *L'Anthropologie* (Paris) **91,** 163–174.

Mallegni, F. & Ronchitelli, A. T. (1989). Deciduous teeth of the Neanderthal mandible from Molare Shelter, Near Scario (Salerno, Italy). *Am. J. phys. Anthrop.* **79,** 475–482.

Mann, A. E., Monge, J. M. & Lampl, M. (1991). Investigation into the relationship between perikymata counts and crown formation times. *Am. J. phys. Anthrop.* **86,** 175–188.

Mann, A. E., Lampl, M. L. & Monge, J. M. (1993). Population variation in the microstructure of human dental enamel. *Am. J. phys. Anthrop.* Suppl. **16,** 138.

Moorrees, C. F. A., Fanning, E. A. & Hunt, E. E. (1963). Age variation of formative stages for ten permanent teeth. *J. dent. Res.* **42,** 1490–1502.

Skinner, M. J. & Sperber, G. H. (1982). *Atlas of Radiographs of Early Man.* New York: Alan R. Liss, 346p.

Smith, B. H. (1991). Dental development and the evolution of life history in Hominidae. *Am. J. phys. Anthrop.* **86,** 157–174.

Smith, P. & Arensburg, B. (1977). A Mousterian skeleton from Kebara Cave. In (B. Arensburg & O. Bar-Yosef, Eds) *Eretz Israel* **13,** 164–176.

Smith, P. & Tillier, A.-M. (1989). Additional infant remains from the Mousterian Strata, Kebara Cave (Israel). In (O. Bar-Yosef & Vandermeersch, Eds) Investigation in South Levantine Prehistory. *Bar International Series* **497,** 323–335. Oxford, England.

Tillier, A.-M. (1979). La dentition de l'enfant moustérien Chateauneuf 2 decouvert à l'abri de Hauteroche (Charante). *L'Anthropologie* **83,** 417–438.

Tillier, A.-M. (1983). L'enfant Néanderthalien du Roc de Marsal (Campagne du Bugue, Dordogne). Le squelette facial. *Ann. Paleont.* **69,** 137–149.

Tillier, A.-M. (1992). The origins of modern humans in Southwest Asia: Ontogenetic aspects. In (T. Akazawa, K. Aoki & T. Kimura, Eds) *The Evolution and Dispersal of Modern Humans in Asia,* pp. 15–28. Hokusensha Publishing Co.

Tompkins, R. L. (1993). The relationship between dental development and other somatic maturation markers in recent humans and Upper Pleistocene hominids. Abstract. *Am. J. phys. Anthrop.* Suppl. **16,** 195–196.

Zilberman, U., Skinner, M. & Smith, P. (1992). Tooth components of mandibular deciduous molars of *Homo sapiens sapiens* and *Homo sapiens neanderthalensis*: A radiographic study. *Am. J. phys. Anthrop.* **87,** 255–262.